PARTIAL REVERSION TO HEXAPROTODONT DENTITION IN HIPPOPOTAMUS, *H. AMPHIBIUS*, LINN.

By R. L. HARGER.

The specimen from Majanji, Lake Victoria, is sub-adult, sex uncertain, but probably female, judging from the size of the lower jaw. In addition to the normal four lower incisors there is an additional small and laterally compressed tooth arising behind the line of and between the 1st and 3rd lower left incisors. At point of emergence from bone the measurements are 14 m.m. x 18 m.m. The tip has been considerably chipped, but judging from the remaining contours, this tooth projected from the bone at least 15 m.m. and probably just managed to cut the gum. On the right side the two incisors are of normal size. On the left side, where the extra tooth occurs, the outer incisor is reduced in size, the socket at jaw level being only 25 m.m. in diameter against 30 m.m. of the corresponding tooth on the right. This is undoubtedly an instance of partial reversion to the less specialized dentition of six lower incisors in certain extinct forms. Four being the normal dentition of existing *H. amphibius* now confined to Africa.

The study of extinct species of the family Hippopotamidae shows that the early and more generalized dentition included six incisors in the lower jar. Flower and Lydekker in " Mammals Living and Extinct " record that " in the Pleistocene and Pliocene of India there are two species having three pairs of incisors in both jaws. Of these *H. palaeindicus* has the second pair in the lower jaw very minute and evidently just about to disappear; from which we learn that it is this pair which is missing in *H. amphibius*. In the more generalized *H. swalensis*, the three incisors of the lower jaw are of equal size. Hexaprotodont species also occur in the Upper Tertiaries of Burma and Algeria."

In the other existing African form, the Pigmy Hippopotamus of West Africa, *Hippopotamus liberiensis* (or *Chœropsis* as some authorities prefer to name it) the incisors are normally reduced to a single pair, but sometimes one or two extra incisors are produced in the lower jaw. During recent years this species has been under close observation at the Zoological Gardens, London, and bred there in 1930.

In the small extinct form from Madagascar, *H. madagascariensis*, Grandidier, of which the writer has examined specimens, the number of the lower incisors varies from the normal four, and is similar to the Liberian species.

Many years ago the writer knew of another example of the existing African hippo from the Lake Bengueulu District, Northern Rhodesia, which had developed an extra incisor. Relying on memory, my notes being lost, this was a well-developed slender tooth projecting three to four inches from the jaw bone.

Hippotamus amphibius.
Showing aberrant dentition
in the incisor region.

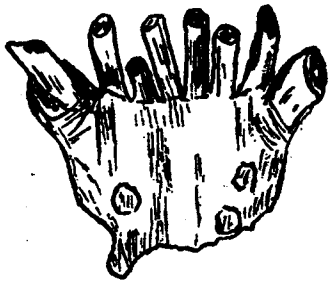

Hippotamus sivalensis, Falconer and Cautley,
after von Zittel and
Smith Woodward.

The subject of this article, supported by the actual specimen now in the Nairobi Museum, confirms the long held opinion that the second incisor is the tooth which has been eliminated in the normal dentition of *H. amphibius*. It also reveals the facts that in this nearly adult specimen the fourth permanent premolar in upper jar is the last tooth to be erupted. In the upper jaw the left deciduous P.M.4 is still in position although much worn and the roots have been absorbed on the lingual side only. The third molars are just coming into function although the first premolars both upper and lower have been shed and their cavities are closed or are closing.

It has been suggested that the extra tooth is an incisor of the milk dentition which has not been shed. The accompanying illustrations are from photographs of a hippo calf from the Sesse Islands, Uganda, collected by the writer (but shot by native) and which was well known to be from three or four months old. Here the four peg-like lower incisors are of the following dimensions: Projection from bone, 10 m.m. average; total length, average 30 m.m.; average diameter, 7 m.m. Only two were just visible above the gum but all could be felt with the finger. In a line behind this deciduous set the crypts of the permanent incisors are already open and hold these developing teeth, the crowns of which are visible. From observations of specimens born in captivity—instance the London Zoological Gardens—it is known that *H. amphibius* begins to shed the milk dentition at about the eighth month. It is therefore improbable that these mere pegs could be capable of further development as their roots are pointed and their cavities apparently closed.

The suggestion has also been put forward that the presence of the extra incisor in the larger jaw is due to the subdivision of a tooth germ. If this is so, careful sectioning will be almost certain to reveal a connection, and the decision will rest on Dr. van Someren's expert dental opinion, if convenient.

Consideration is due to the facts that in the extinct Indian form, *H. palaeindicus*, the second incisor is very small and evidently on the verge of disappearance also that instances of dental reversion are known in other mammalian genera.

For instance, the Bat-eared Fox Otocyon often develops a fourth upper molar. The writer had a specimen in which this tooth was well developed.